Journal of Science and Medicine in Sport xxx (2015) xxx–xxx

Contents lists available at ScienceDirect

Journal of Science and Medicine in Sport

journal homepage: www.elsevier.com/locate/jsams

Original research

Acute hamstring injury in football players: Association between anatomical location and extent of injury—A large single-center MRI report

Michel D. Crema[a,b,c], Ali Guermazi[a,b], Johannes L. Tol[a], Jingbo Niu[d], Bruce Hamilton[a,e], Frank W. Roemer[a,b,f,*]

[a] Aspetar, Orthopaedic and Sports Medicine Hospital, Qatar
[b] Quantitative Imaging Center, Department of Radiology, Boston University School of Medicine, USA
[c] Department of Radiology, Hospital do Coração and Teleimagem, Brazil
[d] Clinical Epidemiology and Training Unit, Department of Medicine, Boston University School of Medicine, USA
[e] Department of Sports Medicine, High Performance Sport New Zealand, New Zealand
[f] Department of Radiology, University of Erlangen-Nuremberg, Germany

ARTICLE INFO

Article history:
Received 29 September 2014
Received in revised form 4 February 2015
Accepted 8 April 2015
Available online xxx

Keywords:
Hamstring
Muscle skeletal
Magnetic resonance imaging
Soccer
Football
Leg injuries

ABSTRACT

Objectives: To describe in detail the anatomic distribution of acute hamstring injuries in football players, and to assess the relationship between location and extent of edema and tears, all based on findings from MRI.
Design: Retrospective observational study.
Methods: We included 275 consecutive male football players who had sustained acute hamstring injuries and had positive findings on MRI. For each subject, lesions were recorded at specific locations of the hamstring muscles, which were divided into proximal or distal: free tendon, myotendinous junction, muscle belly, and myofascial junction locations. For each lesion, we assessed the largest cross-sectional area of edema and/or tears. We calculated the prevalence of injuries by location. The relationships between locations and extent of edema and tears were assessed using a one-sample *t*-test, with significance set at $p < 0.05$.
Results: The long head of biceps femoris (LHBF) was most commonly affected (56.5%). Overall, injuries were most common in the myotendinous junction and in proximal locations. The proximal myotendinous junction was associated with a greater extent of edema in the LHBF and semitendinosus (ST) muscles ($p < 0.05$). Proximal locations in the LHBF had larger edema than distal locations ($p < 0.05$). Distal locations in the ST muscle had larger tears than proximal locations ($p < 0.05$).
Conclusions: The proximal myotendinous junction (LHBF and ST muscles) and proximal locations (LHBF muscle) are more commonly affected and are associated with a greater extent of edema in acute hamstring muscle injury. Distal locations (ST muscle), however, seem to be more commonly associated with larger tears.

© 2015 Sports Medicine Australia. Published by Elsevier Ltd. All rights reserved.

1. Introduction

Muscle injuries of the lower limbs are common in football (soccer) players,[1–3] and over 90% of these affect four major muscle groups, the hamstrings, the posterior calf, the adductors, and the quadriceps group.[4,5] The hamstring muscle complex is most commonly affected by injuries in professional football with a reported prevalence of 37% of all muscle injuries in a large prospective cohort, and accounting for 12% of all injuries.[1,6] Within the hamstring group, the biceps femoris is the muscle most frequently affected.[1,6]

Magnetic resonance imaging (MRI) is considered the reference standard to confirm and evaluate the extent and severity of muscle injuries, including the hamstring complex.[7,8] Previous studies demonstrated that some features of hamstring injuries depicted on MRI such as location,[2,9,10] including the central tendon of biceps femoris involvement, proximal injury (mainly proximal myotendinous junction), and proximal free tendon involvement, as well

* Corresponding author.
E-mail addresses: frank.roemer@aspetar.com, froemer@bu.edu (F.W. Roemer).

http://dx.doi.org/10.1016/j.jsams.2015.04.005
1440-2440/© 2015 Sports Medicine Australia. Published by Elsevier Ltd. All rights reserved.

as extent of injury, [7,11,12] i.e., longitudinal length or the cross-sectional (percentage of) area of injuries, correlate with longer recovery times or risk of recurrent injury.[11,13,14] Most of these studies assessed the extent of injury by measuring a composite of total volume or area taking into account regions of edema with or without tears combined, without differentiating the different manifestations of injury.[15–17]

It might be clinically relevant to know which locations are associated with more severe injury (i.e., macroscopic tears and not only edema; extent of injury), as this can affect treatment decisions and prognosis. Prompt clinical examination at the time of injury may provide important information about the location of the injury,[15] and knowing how the location of the injury relates to the extent of the injury could give initial prognostic information.

The aims of this study were (1) to describe the different anatomical locations of acute injuries within the hamstring complex and within each muscle, in a large retrospective cohort of football players; (2) to measure the extent (cross-sectional area) of edema and/or tear; and (3) to assess the relationship between specific locations or groups of locations and the extent of edema and/or tear.

2. Methods

A retrospective review was performed of all consecutive MRIs of male football players referred to the department of radiology of (blinded) with a clinical diagnosis of acute hamstring injury. For the purpose of this study, only MRI assessments performed within five days following the hamstring injury were considered in our retrospective review. The records we reviewed dated from 2009 to 2012. The players were registered football players from (blinded). This study was approved by the local institutional review board (IRB) which also waived the requirement for signed informed consent due to the retrospective nature of this study (blinded). Only players with an acute hamstring injury and with positive findings on MRI were included in this analysis.

All examinations were performed on a 1.5 T MRI (Magnetom Espree, Siemens, Erlangen, Germany) using a phased-array surface coil strapped over the thigh and centred over the region of maximal tenderness as identified by the player (skin markers were positioned accordingly). The MRI protocol included coronal proton density-weighted (PDw) fat-suppressed (FS) fast spin-echo (FSE) (repetition time (TR) 3900 ms; echo time (TE) 25 ms; field-of-view (FOV) $23 \times 33\,cm^2$; slice thickness 4 mm; interslice gap 1 mm), sagittal PDw FS FSE (TR 3670 ms; TE 25 ms; FOV $26 \times 33\,cm^2$; slice thickness 4 mm; interslice gap 1 mm), axial T2-weighted FS FSE (TR 5720 ms; TE 74 ms; FOV $28 \times 28\,cm^2$; slice thickness 5 mm; interslice gap 1.2 mm), and axial T1-weighted FSE (TR 705 ms; TE 11 ms; FOV $28 \times 28\,cm^2$; slice thickness 5 mm; interslice gap 1.2 mm).

A single radiologist (blinded) with seven years of experience in musculoskeletal radiology and six years of experience in semiquantitative and quantitative MRI assessment first reviewed all MRIs of players with suspected hamstring muscle injuries in order to define positive and negative (no pathology detected) findings. The positive MRIs were evaluated in detail two months after the initial assessment. The MRI reader was blinded to clinical data as well as to other imaging data.

Lesions were initially assessed individually using all MRI sequences acquired in the three planes, in order to evaluate the whole extension and spectrum of injuries depicted. When two (or more) separate non-contiguous lesions were observed in a single muscle, the lesions were regarded as two distinct lesions (i.e., two lesions were recorded). If lesions were found in more than one muscle, again each lesion was recorded separately. Thus, in this study, some subjects could present with more than one acute lesion.

For each hamstring muscle, locations were recorded as follows: (1) proximal tendon, (2) proximal myotendinous junction, (3) proximal muscle belly, (4) distal muscle belly, (5) distal myotendinous junction, (6) proximal myofascial junction, and (7) distal myofascial junction (Fig. 1a). Distal tendons were not taken into account since the majority of the MRIs did not cover the distal insertions of the muscles.

Lesions were defined by any one or more of these findings:

- An area of edema (Fig. 1b), visualized as poorly-defined high-signal intensity on PDw FS sequences.
- Areas of tears (Fig. 1c), with partial or complete discontinuity/disruption of the muscle fibers, seen as well-defined fluid-equivalent high-signal intensity on PDw FS sequences.
- Signal abnormalities around the myotendinous junction (Fig. 1d) and/or the myofascial junction (Fig. 1e), with or without discontinuity of the central tendon and/or the fascia.
- Involvement of the proximal and/or distal tendons, with or without associated fluid collection or hematoma surrounding the aponeurosis of the muscle affected.

For each muscle, lesions were coded as 1 (first lesion), 2 (second lesion), and so on for each additional lesion.

Because the extent of edema is related to clinical outcome and risk of re-injury,[2,7–9,11–15,17] we assessed the presence and the extent of edema on MRI for each lesion. In the axial plane, the slice showing the largest area of edema was used as the reference for measuring the cross-sectional area of edema (in cm^2) in that lesion. This was achieved by manual segmentation of the edema within that slice. As the presence of a macroscopic tear (fiber disruption) is relevant for prognosis,[2,11] since it is associated with longer recovery times when compared to injuries having only edema, we also assessed the presence and the extent of the tear for each lesion. The axial slice showing the largest area of the tear was used as the reference for measuring the cross-sectional area (in cm^2), by manual segmentation. Finally, the specific location of the tear was noted separately.

Descriptive analysis was performed to show the prevalence of acute hamstring lesions, using these parameters:

- The specific muscle location for each muscle: long head of biceps femoris—LHBF; short head of biceps femoris—SHBF; semitendinosus—ST; and semimembranosus—SM.
- The specific locations (described above) and some groups of locations: myotendinous junction; muscle belly; myofascial junction; proximal locations combined; and distal locations combined.

The presence of edema and/or tears in each lesion, as well as the mean value (standard deviation) of the cross-sectional area of edema and area of any tear for each location (and groups of locations described above) in each muscle was assessed.

We considered the LHBF and SHBF as distinct structures since the SHBF does not cross the same number of joints as other hamstring muscles do. We also assessed the average (mean value) of the areas of edema and tear for each muscle in the whole sample. Muscles were evaluated separately due to their distinct anatomy. Further, the relationship between specific locations (including some groups of locations) and the cross-sectional area of edema and tears was assessed using one-sample *t*-test, using the average (mean value) of these features in each muscle in the whole sample as the reference standard for analysis. Finally, we performed linear regression analysis to directly compare the average values of edema and tears between proximal and distal locations overall. Since a single lesion could be present in more than one of the defined locations (as well as the edema or tearing measured for that specific lesion), especially in cases of extensive injury, we considered each location

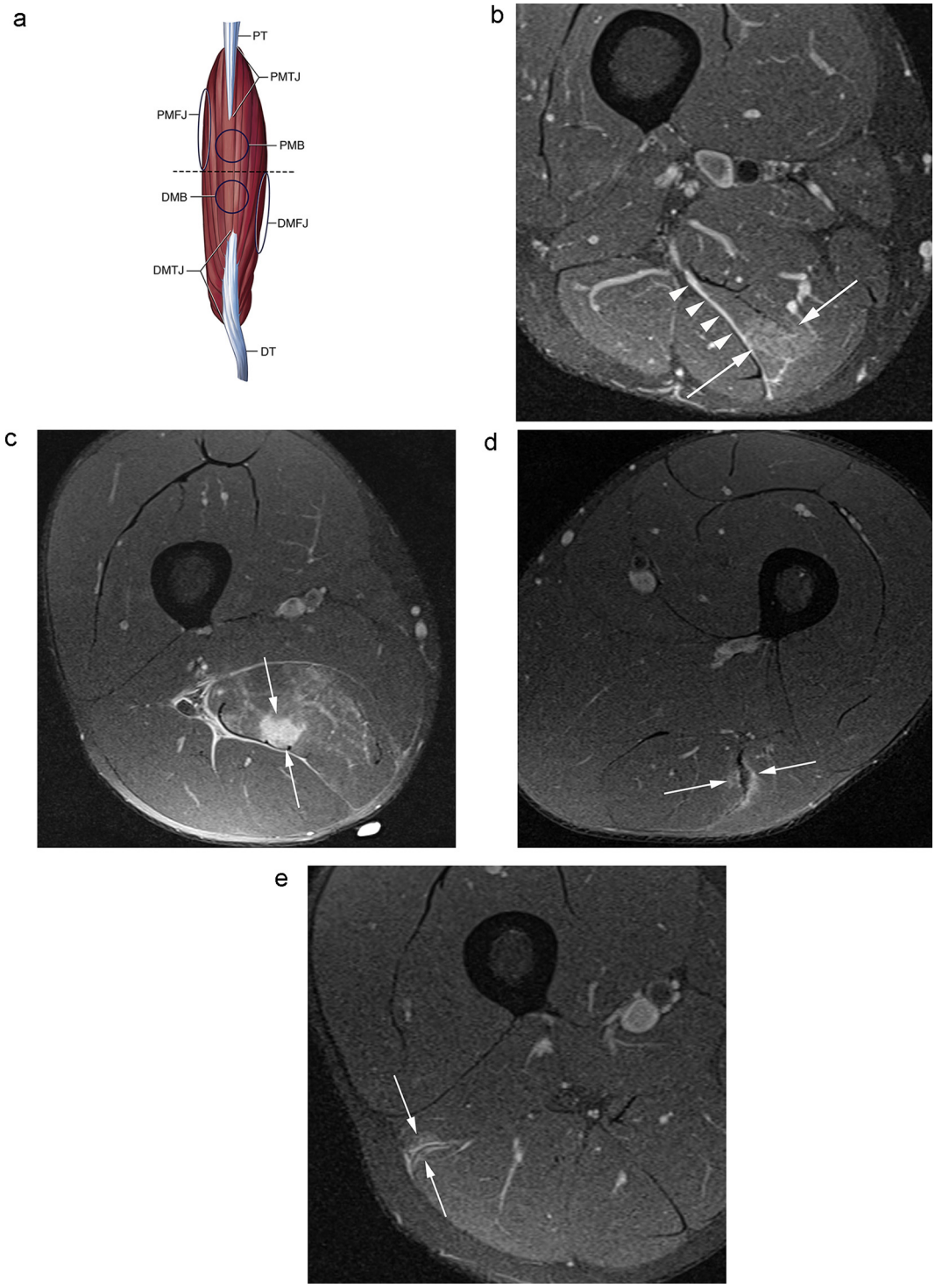

Fig. 1. (a). Schematic drawing of the muscle-tendon-fascia complex showing the different locations evaluated: proximal tendon (PT), proximal myotendinous junction (PMTJ), proximal muscle belly (PMB), proximal myofascial junction (PMFJ), distal muscle belly (DMB), distal myotendinous junction (DMTJ), and distal myofascial junction (DMFJ). The distal tendon (DT) location was not evaluated in this study. (b). Axial PDw FS FSE image showing features of acute semimembranosus injury affecting the distal muscle belly. An area of intramuscular poorly-defined high signal intensity representing edema (arrows) is depicted. Note the thin fluid collection/hematoma along the adjacent deep fascia (arrowheads). Appendix D1 shows manual segmentation of the area of edema. (c). Axial PDw FS FSE image showing features of acute semimembranosus injury affecting the distal muscle belly. An intramuscular tear (arrows) was depicted as a well-defined area of high signal intensity, and it was surrounded by a larger ill-defined area of high signal intensity representing edema. Note a thin fluid collection/hematoma surrounding the semimembranosus fascia. Appendix D2 depicts manual segmentation of the area of tear. (d). Axial PDw FS FSE image showing acute injury features around the proximal myotendinous junction (MTJ) of the long head of biceps femoris muscle. Mild edema surrounds the thickened MTJ (arrows), with intrasubstance signal changes of the adjacent tendon. No discontinuity of the MTJ is depicted. (e). Axial PDw FS FSE image showing acute injury features around the distal myofascial junction (MFJ) of the long head of biceps femoris muscle. Mild edema surrounds the MFJ (arrows), with normal signal and morphology of the adjacent fascia. No discontinuity of the MFJ is depicted.

Please cite this article in press as: Crema MD, et al. Acute hamstring injury in football players: Association between anatomical location and extent of injury—A large single-center MRI report. *J Sci Med Sport* (2015), http://dx.doi.org/10.1016/j.jsams.2015.04.005

Table 1
Prevalence of any MRI feature of acute injury in different locations and muscles (whole sample).

Location	LHBF *N* (%)	ST *N* (%)	SM *N* (%)	SHBF *N* (%)
Proximal tendon	12/393(3.1)	9/393(2.3)	10/393(2.5)	0/393(0)
Proximal MTJ	105/393(26.7)	8/393(2)	29/393(7.4)	0/393(0)
Proximal belly	15/393(3.8)	60/393(15.3)	8/393(2)	9/393(2.3)
Distal belly	25/393(6.4)	10/393(2.5)	5/393(1.3)	9/393(2.3)
Distal MTJ	47/393(12)	9/393(2.3)	12/393(3.1)	1/393(0.3)
Proximal MFJ	9/393(2.3)	8/393(2)	1/393(0.3)	5/393(1.3)
Distal MFJ	41/393(10.4)	0/393(0)	1/393(0.3)	1/393(0.3)
MTJ locations	130/393(33.1)	17/393(4.3)	33/393(8.4)	1/393(0.3)
Belly locations	37/393(9.4)	61/393(15.5)	13/393(3.3)	15/393(3.8)
MFJ locations	49/393(12.5)	8/393(2)	2/393(0.5)	6/393(1.5)
Proximal locations	125/393(31.8)	75/393(19.1)	38/393(9.7)	14/393(3.6)
Distal locations	113/393(28.8)	19/393(4.8)	18/393(4.6)	11/393(2.8)
Any location	222/393(56.5)	96/393(24.4)	54/393(13.7)	22/393(5.6)

LHBF (long head of biceps femoris); ST (semitendinosus); SM (Semimembranosus), SHBF (short head biceps femoris); *N* (number of lesions involving the location); MTJ (myotendinous junction); MFJ (myofascial junction).

of the same lesion to be a separate predictor of edema and/or tear. Regardless of the number of locations affected by the same lesion, lesions in this sample were considered as independent observations. The significance level was set at $p < 0.05$. After a time frame of two months, the same radiologist re-evaluated the MRI (same features) of a random sample of 40 players for intra-reader reliability. Reliability for the evaluation of location, as well as for the presence of edema and/or tear was assessed using kappa statistics. Reliability for the assessment of the area of edema and/or tear was evaluated using intraclass correlation coefficient (ICC). All analyses were performed using SAS version 9.2 software (SAS Institute Inc., Cary, NC, USA)

3. Results

Two hundred and seventy-five male professional football players with MRI-detected acute hamstring injury were included (mean age 25 years, range 18–39 years, standard deviation ± 5.2). A total of 393 lesions were included; 348 had measurable and unequivocal edema (88.6%), and 109 (27.7%) had measurable and unequivocal tears. All of the lesions with tears exhibited concomitant edema. The remaining 45 (11.4%) lesions had very mild changes that were not measurable either around the myotendinous or myofascial junction, or proximal tendon involvement. Two hundred and thirty-nine lesions had only edema, with no tear depicted (60.8%). Twenty one lesions (5.3% of all lesions) affected the proximal tendon, with 9/21 (42.8%) representing partial rupture and 12/21 (57.2%) representing complete rupture or avulsion. A single muscle was affected in 180 of the subjects (65.5%), two muscles were affected in 79 subjects (28.7%), three muscles were affected in 14 subjects (5.1%), and all four hamstring muscles were affected in two subjects (0.7%). A perfect intra-reader agreement was found for the definition of location and for the detection of edema (kappa 1.00). An almost perfect agreement was found for the detection of tears (kappa 0.89 (95% CI 0.76, 1.00), Excellent agreement was found for the assessment of the area of edema (ICC 0.98 (95% CI 0.98, 1.00) and area of tears (ICC 1.00 (95% CI 0.99, 1.00).

The LHBF was the most commonly affected muscle, accounting for 222 lesions (56.5%). For each location assessed separately, the most commonly affected location was the proximal myotendinous junction for the LHBF and SM, the proximal muscle belly for the ST, and both proximal and distal muscle belly for the SHBF. Details of the anatomical distribution are shown in Table 1.

The LHBF muscle was the most commonly affected by edema (54.9%). For the frequencies of edema for specific locations, the most prevalent were the proximal myotendinous junction for the LHBF and SM, the proximal muscle belly for the ST, and both proximal and distal muscle belly for the SHBF. The LHBF muscle was the most commonly affected by tears (67%). By location, the most commonly affected by tears were the proximal myotendinous junction for the LHBF and SM, and the proximal myofascial junction for the ST. The details on distribution of edema and tears in regard to locations for each muscle are presented in **Appendix A. and B.**

For the whole sample, the mean values for cross-sectional edema in each muscle (called here muscle mean value) were 3.17 cm^2 (LHBF), 4.70 cm^2 (ST), 3.59 cm^2 (SM), and 3.04 cm^2 (SHBF). For the sample of lesions having only edema ($n = 348$), the muscle mean values were 3.64 cm^2 (LHBF), 4.74 cm^2 (ST), 4.39 cm^2 (SM), and 3.31 cm^2 (SHBF). Details on the associations between edema size and locations are presented in Table 2.

The mean values for cross-sectional tears in each muscle (muscle mean value) were 0.23 cm^2 (LHBF), 0.28 cm^2 (ST), 0.26 cm^2 (SM), and 0.02 cm^2 (SHBF). For the sample of lesions with tears ($n = 109$), the muscle mean values were 0.67 cm^2 (LHBF), 1.34 cm^2 (ST), 0.81 cm^2 (SM), and 0.6 cm^2 (SHBF). These results are presented in more detail in **Appendix C**.

For the ST muscle, the proximal myotendinous junction location had a greater mean value of edema than the muscle mean value ($p = 0.003$) considering the whole sample. Considering only the sample of lesions with edema, the proximal myotendinous location of the LHBF had a greater mean value of edema (4.45 cm^2; SD 3.61) than the muscle mean value ($p = 0.04$). When comparing the average values of edema and tears between proximal and distal locations, we found significantly larger edema in distal locations of the SHBF muscle ($p = 0.007$) in the whole sample. Considering only the sample of lesions with edema, significantly larger edema was found in proximal locations of the LHBF muscle when compared to distal locations (4.09 cm^2 vs. 3.23 cm^2; $p = 0.02$). Considering only the sample of lesions having tears, significantly larger tears were found in distal locations of the ST muscle when compared to proximal locations (3.47 cm^2 vs. 1.02 cm^2; $p < 0.001$).

4. Discussion

In this sample, the biceps femoris was the most commonly affected muscle, which accords with the literature, followed by the ST and SM muscles. Since injury rates of the ST and SM muscles alternate rank in the current literature, it is difficult to compare our findings regarding these muscles.[2,6,11] In addition, we described in detail specific locations or groups of locations in each of the hamstring muscles, which has not been assessed previously in studies involving football players.[10,14,18] We found that the myotendinous

junction locations as well as proximal locations were more commonly affected by acute injury. For the LHBF, the proximal myotendinous junction location was the most common specific location affected, with the grouped myotendinous junction locations and proximal locations more commonly affected. This is in accordance with previous reports based on smaller samples.[7,14] For the ST muscle, the proximal muscle belly was the most commonly affected location. For the SM muscle, the proximal myotendinous junction was the most commonly affected location. Finally, for the SHBF, proximal and distal belly locations were the most frequently affected by injury.

After identifying the locations of hamstring muscles affected by acute injury, we were interested in determining which location or groups of locations were associated with the extent of injury. To our knowledge, no previous work has attempted to determine which location or groups of locations were associated with extent of injury. Such information would, presumably, be useful for sports medicine clinicians, since the location of the injury can be determined by clinical examination at the time of injury.[15] Since larger hamstring lesions are associated with longer recovery times,[2,7,11] as well as recurrent injury, knowing which locations are associated with larger lesions could potentially provide an early, indirect estimation of the expected time of recovery,[12,13,17] an important prognostic information.

The proximal myotendinous junction location had the largest mean value of edema in the LHBF and ST muscles, which were the most commonly affected muscles in the whole sample (80.9%). We could show that this same location in the LHBF and ST muscles was significantly associated with larger edema when compared to the muscle mean values. Furthermore, we demonstrated that proximal locations overall in the LHBF had significantly larger edema compared to distal locations overall. Previous studies measured the extent of the whole injury when assessing its relationship to clinical features, such as time of recovery and risk of recurrent injury, and it was likely that the extent of edema was measured since a tear (area of fiber disruption) is always surrounded by edema in acute muscle injuries. The fact that we found significant associations between some locations in muscles and the amount of edema is still relevant, as the size of edema correlates with important clinical features.[2,11,13]

Regarding the presence of tears, distal locations in the ST muscle had a significantly greater mean value of tears compared to proximal locations overall when considering only the sample of lesions having tears. Although some proximal locations in the ST and SM exhibited larger mean values of tears in the whole sample included, these associations were not statistically significant. It is worth noting that, despite the fact that proximal locations in all the muscles were more commonly affected by injury, tears in distal locations were larger, i.e. more severe. This is of relevance since it is accepted that the larger the tear the longer the recovery time.[2,11]

Our study has some limitations. We included only players with positive findings of acute hamstring injury on MRI, so there was no control group. We acknowledge potential bias created by having the same reader for the initial review of images and for the subsequent interpretations but tried to minimize this effect by a two months interval between the initial assessment and the actual readings. Ideally, one should assess the extent of injury (e.g., edema and tear) at each location of the muscle, and for that several measurements of edema (less likely tears) would be necessary. However, we were interested in assessing the largest area of injury for a specific lesion so we could actually evaluate the relationships between locations and extent of injury for all locations. If we had assessed the extent of injury for each anatomic part of the muscle, smaller locations would likely have smaller edema (or even tears), whereas larger locations would likely have more extensive changes on MRI. For some locations in some muscles, especially for the SHBF, we

Table 2
Mean values and standard deviation for cross-sectional area of edema in each location in each muscle in the whole sample, and the relationship between locations and extent of edema.

Location of edema separately	LHBF $A = 3.17$		ST $A = 4.70$		SM $A = 3.59$		SHBF $A = 3.04$	
	Edema area (mean, SD)	*p*-value from one-sample *t*-test	Edema area (mean, SD)	*p*-value from one-sample *t*-test	Edema area (mean, SD)	*p*-value from one-sample *t*-test	Edema area (mean, SD)	*p*-value from one-sample *t*-test
Proximal MTJ	3.73 (3.69) from 105 patients	0.1238	8.09 (2.11) from 8 patients	**0.0027***	3.75 (4.26) from 29 patients	0.8390	n/a	n/a
Proximal belly	2.53 (2.17) from 15 patients	0.2709	3.74 (2.63) from 60 patients	**0.0061***	3.24 (1.69) from 8 patients	0.5735	3.32 (3.5) from 9 patients	0.8177
Distal belly	2.72 (1.99) from 25 patients	0.2708	6.65 (3.23) from 10 patients	0.0886	3.06 (2.39) from 5 patients	0.6468	4.12 (3.12) from 9 patients	0.3304
Distal MTJ	3.53 (3.22) from 47 patients	0.4441	4.28 (4.45) from 9 patients	0.7830	5.56 (5.33) from 12 patients	0.2272	1.2 (n/a) from 1 patients	n/a
Proximal MFJ	3.01 (3.11) from 8 patients	0.8864	6.45 (2.95) from 8 patients	0.1371	8.7 (n/a) from 1 patients	n/a	0.58 (0.59) from 5 patients	**0.0007***
Distal MFJ	2.35 (2.48) from 41 patients	**0.0418***	n/a	n/a	0.6 (n/a) from 1 patient	n/a	5 (n/a) from 1 patient	n/a
Different anatomic locations								
Muscle belly	2.5 (1.79) from 37 patients	**0.0300***	3.78 (2.63) from 61 patients	**0.0083***	3.17 (1.89) from 13 patients	0.4386	3.08 (2.76) from 15 patients	0.9604
MFJ	2.49 (2.59) from 48 patients	0.0750	6.45 (2.95) from 8 patients	0.1371	4.65 (5.73) from 2 patients	0.8369	1.32 (1.88) from 6 patients	0.0743
MTJ	3.55 (3.58) from 130 patients	0.2312	6.07 (3.96) from 17 patients	0.1727	3.91 (4.41) from 33 patients	0.6829	1.2 (n/a) from 1 patients	n/a
Proximal vs. distal locations								
Distal	2.95 (2.76) from 111 patients	0.3970	5.53 (3.93) from 19 patients	0.3721	4.59 (4.69) from 18 patients	0.3790	3.94 (2.95) from 11 patients	0.3390
Proximal	3.5 (3.52) from 124 patients	0.3015	4.44 (2.98) from 75 patients	0.4449	3.77 (3.87) from 38 patients	0.7710	2.34 (3.09) from 14 patients	0.4106

The value of area is in cm^2. A = average of edema considering all separate locations of the same muscle (mean value); SD = standard deviation; N/A for edema = no edema detected in such location; LHBF (long head of biceps femoris); ST (semitendinosus); SM (Semimembranosus), SHBF (short head biceps femoris); N (number of lesions involving the location); MTJ (myotendinous junction); MFJ (myofascial junction); n/a (not applicable).
* Statistically significant at $p < 0.05$

did not have a sufficient number of lesions to assess the relationships with adequate power. Further, the field-of-view of most of the MRIs we reviewed did not cover the distal tendons' insertions, an issue that cannot be solved due to the retrospective nature of this study.

5. Conclusion

In conclusion, in this large sample of male football players, the LHBF was the most commonly affected muscle by acute injury, with the proximal myotendinous junction and proximal locations being most prevalent. The proximal myotendinous junction location was associated with a greater extent of edema in the LHBF and ST muscles, with proximal locations overall in the LHBF having a significant larger edema compared to distal locations overall. Regarding tears, we demonstrated that distal locations had more extensive tears in the ST muscle compared to proximal locations. Knowledge of the findings and relationships demonstrated in this study could potentially give useful prognostic information, since previous studies showed that the extent of injury is associated with important clinical features such as time of recovery and risk of re-injury.

6. Practical implications

- This work is the first to assess the relationship between locations of acute hamstring injuries in football players and the extent of injuries (edema and tears) assessed on magnetic resonance imaging (MRI).
- The proximal myotendinous junction and proximal locations are associated with a greater extent of edema in acute hamstring muscle injury.
- Distal locations seem to be more commonly associated with larger tears in acute hamstring muscle injury.
- Knowledge of the findings and relationship between hamstring muscle injury location and extent of edema and tears could potentially provide useful prognostic and clinically relevant information, as it was previously demonstrated that the extent of lesions is associated with time of recovery and risk of muscle re-injury.

Acknowledgments

- The study was funded by ASPETAR, Orthopaedic and Sports Medicine Hospital, Doha, Qatar. No external financial support has been received.
- We wish to thank all staff members of the Department of Radiology at ASPETAR.

Appendix A. Supplementary data

Supplementary data associated with this article can be found, in the online version, at doi:10.1016/j.jsams.2015.04.005

References

1. Ekstrand J, Hagglund M, Waldén M. Epidemiology of muscle injuries in professional football (soccer). *Am J Sports Med* 2011; 39(6):1226–1232.
2. Ekstrand J, Healy JC, Waldén M et al. Hamstring muscle injuries in professional football: the correlation of MRI findings with return to play. *Br J Sports Med* 2012; 46(2):112–117.
3. Junge A, Dvorak J, Graf-Baumann T et al. Football injuries during FIFA tournaments and the Olympic games, 1998–2001: development and implementation of an injury-reporting system. *Am J Sports Med* 2004; 32(1 Suppl.):S80–S89.
4. Volpi P, Melegati G, Tornese D et al. Muscle strains in soccer: a five-year survey of an Italian major league team. *Knee Surg Sports Traumatol Arthroscopy* 2004; 12(5):482–485.
5. Waldén M, Hagglund M, Ekstrand J. UEFA champions league study: a prospective study of injuries in professional football during 2001–2002 season. *Br J Sports Med* 2005; 39(8):542–546.
6. Woods C, Hawkins RD, Maltby S et al. The football association medical research programme: an audit of injuries in professional football—analysis of hamstring injuries. *Br J Sports Med* 2004; 38(1):36–41.
7. Connell DA, Schneider-Kolsky ME, Hoving JL et al. Longitudinal study comparing sonographic and MRI assessments of acute and healing hamstring injuries. *Am J Roentgenol* 2004; 183(4):975–984.
8. Koulouris G, Connell D. Hamstring muscle complex: an imaging review. *Radiographics* 2005; 25(3):571–586.
9. Askling CM, Tengvar M, Saartok T et al. Acute first-time hamstring strains during high-speed running: a longitudinal study including clinical and magnetic resonance imaging findings. *Am J Sports Med* 2007; 35(2):197–206.
10. Comin J, Malliaras P, Baquie P et al. Return to competitive play after hamstring injuries involving disruption of the central tendon. *Am J Sports Med* 2013; 41(1):111–115.
11. Cohen SB, Towers JD, Zoga A et al. Hamstring injuries in professional football players: magnetic resonance imaging correlation with return to play. *Sports Health* 2011; 3(5):423–430.
12. Gibbs NJ, Cross TM, Cameron M et al. The accuracy of MRI in predicting recovery and recurrence of acute grade one hamstring muscle strains within the same season in Australian rules football players. *J Sci Med Sport* 2004; 7(2):248–258.
13. Kerkhoffs GM, van Es N, Wieldraaijer T et al. Diagnosis and prognosis of acute hamstring injuries in athletes. *Knee Surg Sports Traumatol Arthroscopy* 2013; 21(2):500–509.
14. Koulouris G, Connell DA, Brukner P et al. Magnetic resonance imaging parameters for assessing risk of recurrent hamstring injuries in elite athletes. *Am J Sports Med* 2007; 35(9):1500–1506.
15. Schneider-Kolsky ME, Hoving JL, Warren P et al. A comparison between clinical assessment and magnetic resonance imaging of acute hamstring injuries. *Am J Sports Med* 2006; 34(6):1008–1015.
16. Slavotinek JP, Verrall GM, Fon GT. Hamstring injury in athletes: using MR imaging measurements to compare extent of muscle injury with amount of time lost from competition. *Am J Roentgenol* 2002; 179(6):1621–1628.
17. Verrall GM, Slavotinek JP, Barnes PG et al. Assessment of physical examination and magnetic resonance imaging findings of hamstring injury as predictors for recurrent injury. *J Orthop Sports Phys Ther* 2006; 36(4):215–224.
18. Verrall GM, Slavotinek JP, Barnes PG et al. Diagnostic and prognostic value of clinical findings in 83 athletes with posterior thigh injury: comparison of clinical findings with magnetic resonance imaging documentation of hamstring muscle strain. *Am J Sports Med* 2003; 31(6):969–973.